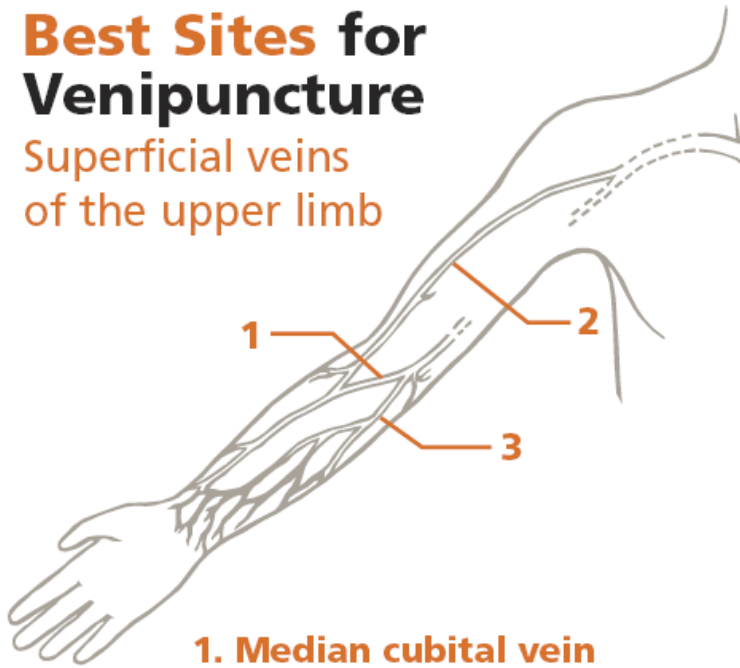




Best Sites for Venipuncture

Superficial veins
of the upper limb



1. Median cubital vein

A superficial vein, most commonly used for venipuncture, it lies over the cubital fossa and serves as an anastomosis between the cephalic and basilic veins.

2. Cephalic vein

Shown in both forearm and arm, it can be followed proximally where it empties into the axillary vein.

3. Basilic vein

Shown in the forearm and arm, it divides to join the brachial vein.

BD Diagnostics

Preanalytical Systems

BD Global Technical Services 1.800.631.0174

BD Customer Service 1.888.237.2762

www.bd.com/vacutainer



Inappropriate Sites for Venipuncture

- Arm on side of mastectomy
- Edematous areas
- Hematomas
- Arm in which blood is being transfused
- Scarred areas
- Arms with fistulas or vascular grafts
- Sites above an IV cannula

Follow your facility's
phlebotomy procedures.

BD Diagnostics

Preanalytical Systems

BD, BD Logo and all other trademarks are property of Becton, Dickinson and Company. ©2004 BD. 6/04 VS5730-2
www.bd.com/vacutainer